

SCLERAL BUCKLING PROCEDURE; AN EXPERIENCE WITH RHEGMATOGENOUS RETINAL DETACHMENT PATIENTS

Mahmood Saeed¹, Adil Saleem², Fouzia Farhat³

ABSTRACT

Background: Rhegmatogenous Retinal Detachment (RDD) is the most common type of Retinal Detachment, secondary to break in neurosensory layer of retina. **Objective:** To determine anatomical and functional improvement and complications, in patients with RDD, treated by scleral buckling procedure. **Patients and Methods:** This descriptive study was conducted in Department of Ophthalmology, Jinnah Post Graduate Medical Centre, Karachi, during July 2004 to December 2005. A total of 40 patients of RRD with proliferative vitreoretinopathy (PVR) grade A and B, under went scleral buckling procedure (SBP). The patients from 5 to 55 years of age and of either sex were included in this study. In addition, patients with diabetes mellitus, coronary vascular disease and other known risk factors for surgery were excluded from the study. All of the patients had uncomplicated RRD with duration of less than three months. Patients were followed up for upto three years for anatomical and functional improvement and complications. **Results:** A three year follow up showed anatomical reattachment after first surgery in 77.5% (31) of the cases and after second surgery in all of the cases. Visual improvement was observed in 75% (30) of the cases while 7.5% (3) cases had worsening of vision and 17.5% (7) cases showed no improvement in their vision. Per operative complication of iatrogenic break, choroidal hemorrhage was also noticed and draining of sub-retinal fluid (SRF) in a total of 7.5% (3) cases, RD in early post-operative period was encountered in 7.5% (3) cases, due to inadequate buckling, whereas in 15% (6) cases, RD developed in late-post operative period. In two of the cases, plomb was exposed. Out of these, one developed endophthalmitis. Causes of RD in early post-operative period was missed hole in two cases, which was dealt with successfully by application of additional plomb. **Conclusion:** Observing the basic surgical principles and thorough pre and post operative examination of the patients, scleral buckling procedure is a safe and effective technique for uncomplicated patients of RRD.

Key Words: Rhegmatogenous retinal detachment, scleral buckling procedure, proliferative vitreoretinopathy.

INTRODUCTION

Rhegmatogenous retinal detachment (RRD) is the most common type of RD and is secondary to a break in the neurosensory layer of retina.¹ For this reason, the treatment is exclusively surgical. In scleral buckling procedure, the break is sealed by diathermy, cryotherapy or laser photocoagulation.² The inward traction over the retina, in particular over the break, is relieved by application of external implant, which is made of silicon³. It is not necessary to drain subretinal fluid (SRF) in all cases⁴. Basic approach is to treat the fresh non complicated cases by scleral buckling and leaving vitrectomy for complicated cases.⁵ Most reports of large consecutive case series indicate that a success rate of 90% or more is now achievable.⁶ However, 10–20% cases require

more than one operation for retinal reattachment. Failure is usually due to inability to recognize breaks during surgery, new break formation, inadequate buckle or Proliferative Vitreoretinopathy (PVR).⁷ Various factors have influence on post-operative recovery despite successful retinal reattachment, including duration of macular detachment, pre-operative visual acuity, cystoid macular edema, macular puckering, and pre operative PVR.^{8,9} Fellow phakic eye with a symptomatic break require observation only. However, in certain high risk cases the second eye should be treated with cryo, laser and explant.^{10,11,12} The objectives of the present study were, to determine anatomical, functional improvement and complications, in patients with RDD, treated by scleral buckling procedure.

PATIENTS AND METHODS

This descriptive study was conducted in Department of Ophthalmology, Jinnah Post Graduate Medical Centre, Karachi, during July 2004 to December 2005. A total of 40 patients of RRD with proliferative vitreoretinopathy (PVR) grade A and B under went scleral buckling procedure (SBP). The patients from 5 to 55 years of age and of either sex were included in this study. Additionally, patients with diabetes mellitus, coronary vascular disease and other known risk factors for surgery were excluded from the study. All of the patients had uncomplicated RRD with

1. Department of Ophthalmology, Sheikh Zayed Medical College/Hospital, Rahim Yar Khan.
2. Laser Vision, Karachi,
3. Dow University of Health Sciences, Karachi.

Correspondence: Prof. Dr. Mehmood Saeed

Cell No . 0333-2213846

Email: mahmood_saeed068@yahoo.com

duration of less than three months. Patients were followed up for upto three years for anatomical and functional improvement and complications. Most of these cases were operated under local anesthesia and sedation, except for children and adults undergoing second surgery. Bridle sutures around all the four recti were placed after periotomy and tenon clearance. The break was marked with stain usually after drainage of SRF. Chorioretinal adhesion was achieved by confluent cryo application around the break. Buckling explants were sutured to the eye with 5/0 ethibond mattress suture. Explants were selected to be sufficiently large to support the break with a margin of 1 – 2mm and of reasonable height to relieve vitreoretinal traction. Length and configuration of implant were selected on the character of break. For dialysis, wide breaks and closely grouped breaks, we applied circumferential buckle. Radial plomb was applied in posteriorly located breaks. Intravitreal air injected as an internal tamponade and intraocular pressure was monitored by direct palpation, Schoitz tonometry and fundus examination. Prophylactic antibiotic and symptomatic treatment were instituted in the post operative period. A short course of systemic steroid was added on fifth post-operative day to overcome vitritis. Snellens visual acuity chart used after refraction in the post-operative period and follow up visits. Indirect ophthalmoscopy and B Scan (if media was hazy) was utilized to look into anatomical out come. Some patients received both radial and circumferential plombs, 360 degree encirclement silicon band (2.5mm) was applied to all patients who were aphakic, pseudophakic, those having multiple breaks or where we were expecting invisible breaks in the periphery. The data was collected on a specially designed proforma containing operative and follow up notes and entered in SPSS 10 Version. For descriptive statistics, frequencies were calculated.

RESULTS

The distribution of the patients by sex is shown in Fig I. Twenty seven out of 40 (67.5%) patients were phakic, 9 (22.5%) were pseudophakic while remaining 4 (10%) were aphakic. Most of the patients, 23 (57.5%) were emmetropic, 14 (35%) were myopic and 3 (7.5%) were hypermetropic. Extent of retinal detachment is shown in Fig. II

and type of retinal break is shown in Fig. III.

Fig: I Sex Distribution (n=40)

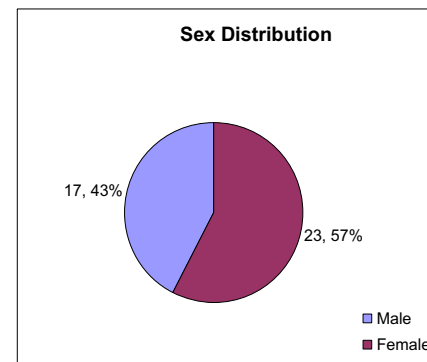


Fig: II Extent of Retinal Detachment (n=40)

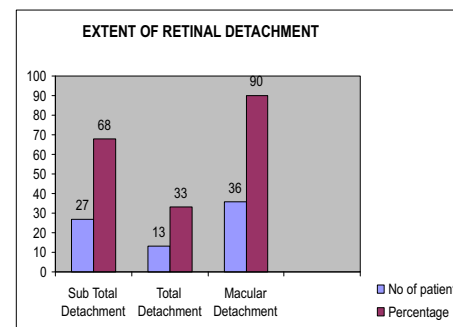
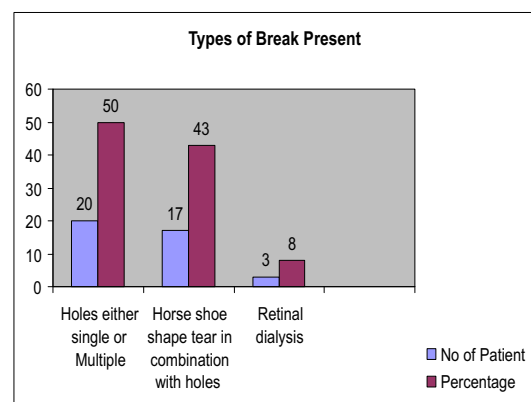


Fig:III Types of Break (n=40)



Eighteen to thirty-six months of follow up showed anatomical reattachment in 31 (77.5%) cases. Among the remaining 9 cases, second surgery was done in four selected cases, while the rest were referred to vitreoretinal surgeon. The degree of visual acuity after surgical procedure was modest where 30 (75%) of the patients experienced improvement in their vision. However, 7 (17.5%) patients showed no

improvement in visual acuity (V_A) and 3 (7.5) had drop in existing visual acuity. The V_A better than 6/18 was achieved in 7 (17.5%) of the patients, while better than 3/60 in 19 (47.5%) of the cases, table I and table II.

Table I:
Functional Success Rate (n=40)

Post operative Visual Acuity	Patients	Percentage
Same as preoperative level	7	17.5
Improved 2 or more lines	30	75
Worse than preoperative level	3	7.5

Table II:
Comparative Preoperative and Postoperative Visual Acuity (n=40)

Best corrected Visual Acuity	Pre-operatively cases	Post-operatively cases
Projection of Light absent	0 (0%)	2 (5%)
Projection of Light present	4 (10%)	1 (2.5%)
Hand movement perceived	23 (57.5%)	0 (0%)
Between 1/60-3/60	9 (22.5%)	18 (45%)
Between 4/60-5/60	3 (7.5%)	9 (22.5%)
Between 6/60-6/24	0 (0%)	3 (7.5%)
Between 6/18-6/9	1 (2.5%)	7 (17.5%)

Table III:
Early & Late Post Operative Complications (n=40)

Complications	Patients	Percentage
Residual Subretinal fluid	3	7.5
Retinal redetachment	3	7.5
Misplaced plomb over the break	2	5
Fishmouthing of the break	1	2.5
Raised flap of dialysis	1	2.5
Vitreous haemorrhage	1	2.5
Grade C Proliferative vitreoretinopathy	6	15
Plomb exposure	3	7.5
Endophthalmitis	1	2.5
Macular Pucker	1	2.5

Per-operative complication were noticed in 7 (17.5%) patients. Out of which, one had inferior rectus damage, one case suffered from an Iatrogenic break, two cases encountered choroidal hemorrhage and one patient had vitreous hemorrhage during surgery immediately after cryo application, whereas one patient suffered raised intraocular pressure and one developed post-subcapsular cataract during air injection.

In the early post-operative period, lid edema was noticed in all the patients. Significant extra ocular

movement limitation was noticed in one (2.5%) case. In one (2.5%) patient, there was accidental touching of needle to the posterior capsule while injecting air in the vitreous cavity. Raised intra ocular pressure was noticed in 1 (2.5%) patient, which was managed medically. There was residual sub-retinal fluid in 3 (7.5%) patients. At around the 15th post-operative day, SRF was still noticed in about 3 (7.5%) cases. We found that these 3 (7.5%) patients started to develop retinal detachments which were due to missed holes. Also as the view cleared off, we noticed hemorrhage in the vitreous cavity in 1 (2.5%) patient. Extra ocular movement limitation was detected in 1 (2.5%) patient. At around 3 months PVR was noticed in the fundus of 8 (20%) patients; among these 2 (5%) had grade B, while 6 (15%) had grade C PVR. In all these patients PVR was the reason for failed surgery and retinal detachment. Macular pucker developed in 1 (2.5%) patient resulting in profound drop in post operative visual acuity. Silicon plomb were found to be exposed in 3 (7.5%) patients that also caused endophthalmitis in 1 (2.5%) patient, however it was managed medically and vision was salvaged. All these exposed plombs were removed and there was detachment of retina in 1 (2.5%) case subsequent to plomb removal (Table III).

DISCUSSION

In cases of simple retinal detachment, conventional buckling surgery is the favored surgical approach.¹⁰ Minimal-invasive techniques like the balloon operation or pneumatic retinopexy are chosen by less than 5% of the surgeons.¹¹ For more complicated retinal detachments a strong trend towards primary vitrectomy becomes apparent. With modern diagnostic and surgical techniques, 90% or greater success rate of repairing detachment is expected.¹²⁻¹⁴ Shwartz et al⁵ reported in their study (carried on 227 eyes) that one hundred eighty-six eyes (82%) achieved retinal reattachment with 1 scleral buckling procedure. An additional 30 eyes (13%) achieved retinal reattachment after 1 or more additional vitreoretinal procedures.

In this study, 40 patients of RRD of 3 months duration or less had scleral buckling procedure performed upon them that were followed up for the detection of complications and determination of anatomical and functional success.

The anatomical success rate in our study is consistent with those of studies mentioned above.

Many studies¹⁶⁻¹⁸ were done previously showing that

cases with larger extent of retinal detachment, more advanced preoperative PVR and poorer preoperative visual acuity have less favorable anatomical and functional results.¹⁹⁻²¹ Variables that yielded an unfavorable outcome in our study were post-operative PVR, inability to detect break pre or per operatively, complications of SRF drainage and post-operative plumb exposure. PVR is reported by many researchers as one of the most common cause of late retinal redetachment.²² Hooymans in his study reported that in 6% of the eyes, PVR was responsible for the initial surgical failure.²³ We have encountered PVR in 15% of cases in our study causing recurrent detachment in 15% of the cases and is the major cause of failure of primary buckling surgery in our study.

Appearance of new retinal breaks after treatment of retinal detachments is well recognized and is probably due to persistent or progressive vitreoretinal traction. New retinal breaks have been reported in 1.1% to 13%. In the study by Lincoff²⁴ new tear formation postoperatively was found in 3.9% and by Racheal and Burton²⁵ in 7.7% of cases, while we were able to find it in 7.5% cases and attributed it to missed holes in 5% and as a complication of SRF drainage (Iatrogenic break) in 2.5% of cases. These breaks accounted for surgical failure in 5% of cases in our study.

Serious complications are more frequently associated with drainage of subretinal fluid than any other step in the operation. Chignell²⁶ in his study had encountered 7.5% complication rate during SRF drainage, of which 4.5% had bleeding while 3% had vitreous loss. Wilkinson and Bradford²⁷ reported 5.6% complication rate of which bleeding contributed for 3% while retinal incarceration occurred in 2.2% of cases along with retinal holes in 0.54%. Hilton²⁷ reported that around 4.3% of cases had bleeding. In our study we found that complications occurred in 7.5% of cases of which 5% had choroidal haemorrhage and 2.5% had vitreous haemorrhage following an iatrogenic break (retinal hole) while draining the SRF. Other complications that we encountered in our study included residual SRF, fishmouthing over the break, misplaced plumb over the break, cataract, plumb exposure, endophthalmitis and macular pucker.

Chignell²⁵ reported that misplaced plumb causing inadequate buckling leading to surgical failure was the cause of 27% of the overall failures. While

Rachal and Burton²⁴ in their study attributed it to only 10% of cases. In our study, 7.5% of cases had complications due to inadequate buckling. 5% had misplaced plumb over the break. The missed hole in 2.5% of cases leading to RD and subsequently requiring plumb readjustment. There was fishmouthing of break in another 2.5% of cases requiring additional buckle placement and raised flap over a dialysis requiring subsequent laser photocoagulation in 2.5% of cases. Haden²⁸ reported endophthalmitis within 2 weeks postoperatively in 3.6% cases and Russo and Ruiz²⁹ reported it in up to 7.1% within 6 weeks. In our study, it occurred within 6 weeks and was present in 2.5% of cases. This is because of exposed infected plumb.

The rate of recurrent detachment after removal of infected scleral buckling material ranges from 3.2% to 33%. Deokule³⁰ reported that 8.3% of patients while Lindsey and coworkers demonstrated that 38% of the eyes developed recurrent detachment or become phthisical after removal of scleral buckling material.^{31,32} In our study RD developed in 33% of cases after removal of exposed plumbs.

Macular Pucker is one of the more common causes of a late decrease in vision after retinal reattachment surgery.³³ In different studies, macular pucker has been reported in 4% to 8% of cases. There is usually a latent period of 6 to 12 weeks between retinal reattachment surgery and the onset of symptoms due to epiretinal proliferation. In our study, 2.5% of cases developed macular pucker after a latent period of around 12 weeks causing a late deterioration of vision. The results of our study showed that the complications and reasons of redetachment are consistent with the above-mentioned studies.

Although anatomic success rates are high enough, functional improvement in vision once the macula is reattached is also satisfactory. We have demonstrated in our study that 75% of cases showed an improvement in their visual acuity of 2 or more lines on Snellen acuity chart, that in V_A is statistically significant ($P=0.003$). Even though many factors have been found to influence the visual outcome of RD surgery, the most important predictor of visual recovery is the preoperative visual acuity that is largely related to macular attachment. In most of the macula off detachment reports showed a post operative median visual acuity of 6/12³⁴, our study was able to show that only 17.5% patient were able to improve to 6/18 or better. We have attributed this loss of recovery of vision to poor pre operative visual

acuity and longer duration of macula off retinal detachment in most of our patients. In our study, 97.5% (39/40) of patients had vision less than 6/60 preoperatively. Poor preoperative vision is associated with a reduced less chance of good postoperative vision. Eyes with preoperative visual acuity of less than 6/60 are far less likely to obtain postoperative vision of 6/18 or better than eyes with preoperative visual acuity of 6/60 or better. Progressive permanent macular damage occurs during the first days after the detachment of macula, and vision rarely returns to the normal after 5 days of involvement. Final vision rarely improves to better than 6/18 after 1 week of macular detachment. Thereafter, about one line to final vision is lost for each week of detachment up to 1 month; about one line is lost for each 10 to 11 days during the second month of detachment. Yang³⁴ reported that postoperative VA of 6/12 or better was found in 53.6% of eyes with duration of macular detachment with in 7 days, and 29.7% of eyes with macular detachment for more than 7 days. In our study, as we have included patients who have detachment as long as 3 months duration, that is why only 17.5% of our patients recover their final vision better than 6/18. Still, the preoperative visual acuity is the single factor having the best correlation with the final visual result. Better initial vision correlates with better final vision, regardless of the duration of macular detachment. Visual recovery after successful surgery of the macula for rhegma-togenous retinal detachment continues to be an important topic for ophthalmologists. Vitreo retinal surgeons should be aware of the fact that visual function based on acuity testing may continue to improve in the long term, most notably it depends on two factors, good preoperative vision and shorter duration of macular detachment (30 days or less).³⁵

CONCLUSION

Observing basic surgical principles and thorough pre and post operative patient's examination, scleral buckling procedure is a safe and effective technique for selected patients of retinal detachments. These patients should have primary, uncomplicated rhegmatogenous retinal detachments and preferably should be phakic.

REFERENCES

1. Kapran Z, Uyar OM, Bilgin BA, Kaya V, Cilsim S ,
2. Veckeneer M, Van Overdam K, Bouwens D, Feron E, Mertens D, Peperkamp E et al. Randomized clinical trial of cryotherapy versus laser photocoagulation for retinopathy in conventional retinal detachment surgery. *Am J Ophthalmol.* 2001;132:343-7
3. Ho CL, Chen KJ, See LC. Selection of scleral buckling for primary retinal detachment. *Ophthalmologica.* 2002 ;216:33-9
4. Haider SA, Awan AR, Chohan A, Anwar A. To drain or not to drain? The place of drainage of sub-retinal fluid in retinal re-attachment surgery. *Pak J Ophthalmol.* 2001;17:82-5
5. Schmidt JC, Rodrigues EB, Hoerle S, Meyer CH, Kroll P. Primary vitrectomy in complicated rhegmatogenous retinal detachment--a survey of 205 eyes. *Ophthalmologica.* 2003;217:387-92
6. Sullivan PM, Luff AJ, Aylward GW. Results of primary retinal reattachment surgery: a prospective audit. *Eye* 1997 ;11:869-71
7. Hooymans JM, De Lavalette VW, Oey AG. Formation of proliferative vitreoretinopathy in primary rhegmatogenous retinal detachment. *Doc Ophthalmol.* 2000;100:39-42
8. Ahmadi H, Entezari M, Soheilian M, Azarmina M, Dehghan MH, Mashayekhi A . Factors influencing anatomic and visual results in primary scleral buckling. *Eur J Ophthalmol.* 2000;10:153-9
9. Sabates NR, Sabates FN, Sabates R, Lee KY, Ziaminski MC. Macular changes after retinal detachment surgery. *Am J Ophthalmol* 1989;108:22-29
10. Greven CM, Wall AB, Slusher MM. Anatomic and visual results in asymptomatic clinical rhegmatogenous retinal detachment repaired by scleral buckling. *Am J Ophthalmol.* 1999 ;128:618-20
11. Mastropasqua L, Carpineto P, Ciancaglini M, Falconio G, Gallenga PE. Treatment of retinal tears and lattice degenerations in fellow eyes in high risk patients suffering retinal detachment: a prospective study. *Br J Ophthalmol.* 1999;83:1046-9
12. Barq RA, Khan T. Prophylactic management of retinal detachment. *Pakistan J Ophthalmol.* 2000 ;16:38-46
13. Rosman M, Wong TY, Ong SG, Ang CL. Retinal detachment in Chinese, Malay and Indian residents in Singapore: a comparative study on risk factors, clinical presentation and surgical outcomes. *Int Ophthalmol.* 2001;24:101-6.
14. Grizzard WS, Hilton GF, Hammer ME, Taren D. A multivariate analysis of anatomic success of retinal detachments treated with scleral buckling. *Graefes Arch Clin Exp Ophthalmol* 1994;232:1-7
15. Schwartz SG, Kuhl DP, McPherson AR, Holz ER, Mieler WF. Twenty-year follow-up for scleral buckling. *Arch Ophthalmol.* 2002 ;120:325-9
16. Feltgen N., Weiss C, Wolf S, Ottenburg D, Heimann H, and SPR Study Group)
17. Michael X. Repka, MD; Betty Tung, MS; William V. Good, MD; Michael Shapiro, MD; Antonio Capone, Jr, MD; John D. Baker, MD; Charles C. Barr, MD; Dale L. Phelps, MD; W.A. J. van Heuven, MD) *Arch*

- Ophthalmology.2006;124:24-30.
18. Ahmadi H, Entezari M, Soheilian M, Azarmina M, Dehghan MH, Mashayekhi A, et al. Factors influencing anatomic and visual results in primary scleral buckling. *Eur J Ophthalmol.* 2000;10:153-9
 19. Zhioua R, Malek I, N Boussen I, Chaker N, Ouertani A. Functional results of rhegmatogenous retinal and macular detachment. *Tunis Med.* 2002;80:681-4
 20. Halberstadt M, Brandenburg L, Sans N, Koerner-Stiefbold U, Koerner F, Garweg JG. Analysis of risk factors for the outcome of primary retinal reattachment surgery in phakic and pseudophakic eyes. *Klin Monatsbl Augenheilkd.*2003;220:116-21
 21. La Heij EC, Derhaag PF, Hendrikse F. Results of scleral buckling operations in primary rhegmatogenous retinal detachment. *Doc Ophthalmol.* 2000;100:17-25
 22. Hooymans JM, De Lavalette VW, Oey AG. Formation of proliferative vitreoretinopathy in primary rhegmatogenous retinal detachment. *Doc Ophthalmol.* 2000;100:39-42
 23. Lincoff H. Should retinal breaks be closed at the time of surgery ?in Brockhurst RJ, Borouchoff SA, Hutchinson BT, Lessell S (eds). *Controversy in ophthalmology*, Philadelphia, W.B.Saunders, 1977. 582-98
 24. Rachal WF, Burton TC. Changing concept of failure after retinal detachment surgery. *Arch ophthalmol* 1979;97:480
 25. Chignell AH, Fison LG, Davies EWG. Failure in retinal detachment surgery. *Br J Ophthalmol* 1973;57:523
 26. Wilkinson CP, Bradford RH Jr. Complication of drainage of subretinal fluid. *Retina* 1984;4:1
 27. Hilton GF, Maclean EB, Norton EWD. *Retinal detachment*, 3rd edition Rochester, American Academy of Ophthalmology;1979
 28. Haden OB. Infection after retinal detachment surgery. *Aust N.Z.J.Ophthalmol* 1986;14:69
 29. Russo CE, Ruiz RS. Silicone sponge rejection. Early and late complication of retinal detachment surgery. *Arch Ophthalmol* 1971;85:647
 30. Deokule S, Reginald A, Callear A. Scleral explant removal: the last decade. *Eye* 2003 ;17:697-700
 31. Lindsey PS, Pierce LH, Welch RB. Removal of scleral buckling elements. Causes and complications. *Arch. Ophthalmol* 1983;101:570
 32. Framme C, Roider J, Hoerauf H, Laqua H. Complications after external retinal surgery in pseudophakic retinal detachment--are scleral buckling operations still current? *Klin Monatsbl Augenheilkd.* 2000 ;216:25-32
 33. Lobes LA Jr, Burton TC. The incidence of macular pucker after retinal detachment surgery. *Am J Ophthalmol* 1978; 85:72
 34. Yang CH, Lin HY, Huang JS, Ho TC, Lin CP, Chen MS et al. Visual outcome in primary macula off rhegmatogenous retinal detachment treated with scleral buckling. *J Formos Med Assoc.*2004;103:212-7
 35. Kusaka S, Toshino A, Ohashi Y, Sakaue E. Long-term visual recovery after scleral buckling for macula-off retinal detachments. *Jpn J Ophthalmol.* 1998;42:218-22

