

# RUPTURED INFECTED FEMORAL PSEUDOANEURYSM IN IV DRUG ABUSERS: LIGATION UNDER LOCAL ANESTHESIA

Ghulam Hassan,<sup>1</sup> Imtiaz Ahmad,<sup>1</sup> Gulzar Ahmad<sup>1</sup>

## ABSTRACT

**Background:** IV drug abusers usually present with life threatening hemorrhage from ruptured infected femoral pseudoaneurysm in emergency. Back up of family, friends and resources are marginal with these patients. In literature many procedures from simple debridement to extra anatomic bypass have been reported. **Objective:** To assess the outcome of ligation of external iliac artery under local anesthesia in terms of survival, limb salvage and feasibility. **Methodology:** This cross sectional study was conducted in Department of Surgery, Quaid e Azam Medical College, Bahawalpur. Duration of study was five years from 1<sup>st</sup> December 2010 to 31<sup>st</sup> December 2015. All patients presenting with bleeding or ruptured femoral pseudoaneurysm in this time span were admitted. Pressure dressing over bleeding aneurysm was done; wide bore peripheral IV line/CV line was passed; fluid resuscitation was started; broad spectrum antibiotics were injected; request for blood arrangement sent and necessary investigations were sent; special consent was taken. Local Anesthesia was injected in the groin just above the aneurysm, ketamine given when needed. External iliac artery was explored in supra inguinal position and ligated. Data regarding age, gender, drug of abuse, vascular status of the limb, need for blood transfusion during procedure, life safety, limb salvage was analyzed. Data was entered and analyzed by using SPSS version 20. **Results:** We ligated external iliac artery just proximal to aneurysm in 48 patients under local anesthesia. Life and limb was saved in 43 (89.5%) patients. Five patients (10.5%) required above knee amputation later. **Conclusion:** Ligation of external iliac artery under local anesthesia in ruptured pseudo aneurysms is simple and safe.

**Keywords:** IV drug abuser, Rupture, Pseudoaneurysm, ligation, External iliac artery

## INTRODUCTION

Drug abuse is an increasing social and health problem. Approximately 16 million people abuse intravenous route for drug addiction worldwide.<sup>1</sup> The commonest site for this purpose is femoral vein at groin because it is a big vein present in guide of femoral artery and both hands are free and can be used for procedure.<sup>2</sup> Repeated punctures under septic conditions and finally inadvertent femoral artery puncture leads to formation of infected pseudoaneurysm, which can rupture resulting in hemorrhage and death.<sup>3</sup> This condition is not only limb threatening but also life threatening and creates a great challenge for emergency surgeon.<sup>4</sup> Inadvertent intra-arterial injection can also result in endarteritis and thrombosis resulting in distal ischemia and gangrene.<sup>5</sup> Additionally these patients have concomitant viral infections like hepatitis B, hepatitis C, HIV due to poor hygiene, septic conditions and sharing of the needles.<sup>2</sup> Few vascular surgeons, adopt an aggressive procedure; excision of the aneurysm along with revascularization with synthetic or autogenous vein grafts in extra-anatomical position.<sup>6,7</sup> Many surgeons opt minimal procedure of ligation and excision to save the life and delayed vascularization if the limb becomes ischemic later on.<sup>8</sup> Back up of friends and family is marginal and most patients have broken marital and family

life.<sup>8,9,10</sup> Blood arrangement is problematic and anesthetist are usually reluctant in such conditions. We opted to ligate external iliac artery under local anesthesia to overcome this surgical emergency and save the life.<sup>11,12,13</sup> The objective of this study was to determine the outcome of ligation of external iliac under local anesthesia in terms of life safety, limb salvage and feasibility.

## METHODOLOGY

This cross sectional study was conducted in department of Surgery, Quaid e Azam Medical College Bahawalpur from 1<sup>st</sup> December, 2010 to December, 2015. All patients presenting with bleeding or ruptured femoral pseudoaneurysm in this time span were admitted. Pressure dressing over bleeding aneurysm was done; wide bore peripheral IV line/CV line was passed; fluid resuscitation was started; broad spectrum antibiotics were injected; request for blood arrangement sent and necessary investigations were sent; special consent was taken. Local Anesthesia was injected in the groin just above the aneurysm ketamine given their needed. External iliac artery was explored in supra inguinal position and ligated. Data regarding age, gender, drug of abuse, vascular status of the limb, need for blood transfusion during procedure, life safety, limb salvage was analyzed. Data was entered and analyzed by using SPSS version 20.

1. Department of Surgery, Quaid e Azam Medical College, Bahawalpur, University of Health Sciences Lahore, Pakistan.

**Correspondence:** Dr. Ghulam Hassan, Senior Registrar, Department of Surgery, Quaid e Azam Medical College, Bahawalpur, Pakistan.

**E-mail:** hassansurgeon@gmail.com

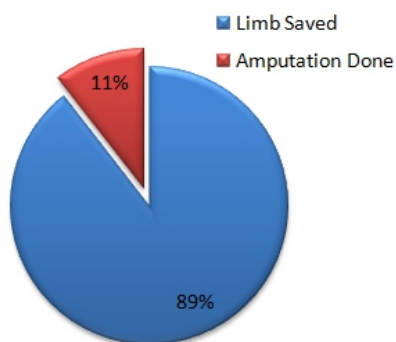
**Received:** 22-12-2017

**Accepted:** 13-02-2018

## RESULTS

In this study, all patients were male. The mean age of presentation was  $22 \pm 8.6$  years, 54% of the patients used to inject a combination of diazepam, pentazocin and chlorpheniramine maleate, 30% of the patients used to inject Diazepam; 16% used to inject pentazocin. At presentation, ipsilateral dorsalis pedis artery and posterior tibial artery were palpable in 43 patients and were not palpable in 5 patients. Local anesthesia was successful in 45 patients. Three patients required additional ketamine along with local anesthesia. Ligation of external iliac artery was performed in all patients. No patient required blood transfusion during the procedure. There was no death during the procedure and post operatively. In 43 patients (89.5%) limb was saved. 5 Patients (10.5%) required above knee amputation later due to leg gangrene.(Figure I)

**Figure I: Outcome of ligation of external iliac artery**



## DISCUSSION

In this study, all patients were young male with mean age of 22 years. This can be due to unemployment and failure in examination and love which direct these individuals to drug addiction. Most of these patients used combination of drugs diazepam, pentazocin and chlorpheniramine because these drugs are cheap and available.

Revascularization is mostly performed with venous or synthetic graft applied in the same or extra-anatomical location.<sup>6,9</sup> Great saphenous vein is generally fibrosed and thrombosed due to repeated puncture so prosthetic graft is required which is costly. Surgical procedure becomes more lengthy and tedious and requires general anesthesia and intraoperative blood transfusions. There is high reinfection risk of prosthetic graft

even placed in extra-anatomic site through obturator foramen. Patients abuse these reconstructed artery again which is stigmatic.<sup>10</sup> Lashkarizadeh described primary repair of the artery with over sewing in 5 patients with good results.<sup>11</sup> Revascularization needed or not: internal iliac artery is clamped and oxygen saturation of toes is monitored on pulse oximeter. Oxygen saturation of toes after clamping of external iliac artery remained above 90% in all patients.<sup>12</sup>

In a series of 72 patients, Saini et al, performed ligation of the artery and excision of aneurysm. Only 4 patients required amputation.<sup>13</sup> Arora et al, did simple arterial ligation without reconstruction resulting in no amputation but mild claudication.<sup>14</sup> Reddy did simple arterial ligation in 39 patients resulting in two amputations later on.<sup>15</sup>

We did simple ligation of external iliac artery just proximal to aneurysm in 48 patients under local anesthesia. Life and limb was saved in 43 patients. Five patients required above knee amputation and these patients had absent posterior tibial and dorsalis pedis arteries were not palpable even at the time of presentation. All other patients had healthy limbs at the time of discharge. There was no need of delayed revascularization.

## CONCLUSION

Ligation of external iliac artery under local anesthesia in ruptured pseudoaneurysms is simple and safe method in saving life and limb of the patient. No need for such great expertise as is required in excision and revascularization. Local anesthesia is effective in most patients but only few patients require additional ketamine. This procedure can be carried out without blood transfusion during operation.

## REFERENCES

- Mathers BM, Degenhardt L, Philips B. Global epidemiology of injecting drug use and HIV among people who inject drugs: a systematic review. *The Lancet* 2008;372 : 1733–1745.
- Behera A, Menakuru SR, Jindal R. Vascular complications of drug abuse: An Indian experience. *ANZ J Surg* 2003;73:1004–7.
- Warner RM, Srinivasan JR. Protean manifestations of intravenous drug use. *Surgeon* 2004;2:137–40.
- Yellin AE. Ruptured mycotic aneurysm: A complication of parenteral drug abuse. *Arch Surg* 1977;112:981–6.
- Coughlin PA, Mavor AL. Arterial Consequences of Recreational Drug Use. *Eur J Vasc Endovasc Surg* 2006; 32(4): 389–396.

6. Patel KR, Semel L, Clauss RH. Routine revascularization with resection of infected femoral pseudoaneurysms from substances abuse. *J Vasc Surg*. 1988;8:321–8.
7. Benjamin ME, Cohn EJ Jr, Purtill WA, Hanna DJ, Lilly MP, Flinn WR. Arterial reconstruction with deep leg veins for the treatment of mycotic aneurysms. *J Vasc Surg* 1999;30:1004–15.
8. Johnson JR, Ledgerwood AM, Lucas CE. Mycotic aneurysm. New concepts in surgery. *Arch Surg* 1983;118:577–82.
9. Levi N, Rordam P, Jensen LP, Schroeder TV. Femoral pseudoaneurysm in drug abusers. *Eur J Vasc Endovasc Surg* 1997;13:361–2.
10. Salehian MT, Shaid N, Mohseni M, Ghodoosi I, Marashi SA, Fazel I. Treatment of infected pseudoaneurysm in drug abusers: Ligation or reconstruction? *Arch Iran Med* 2006;9:49–52.
11. Lashkarizadeh M.R., Ashrafanguie M., Ashrafanguie M. Surgical management of femoral artery pseudoaneurysms secondary to drug abuse. *J Coll Phys Surg Pak* 2011;21(11):672–675.
12. Qui J. The treatment of infected femoral artery pseudoaneurysms secondary to drug abuse: 11 years experience at a single institution. *Ann Vasc Surg* 2016;36:35–43.
13. Saini N.S. Infected pseudoaneurysms in intravenous drug abusers: ligation or reconstruction *Int J Appl Basic Med Res* 2014;4:23–26.
14. Arora S, Weber MA, Fox CJ, Neville R, Lidor A, Sidawy AN. Common femoral artery ligation and local debridement: A safe treatment for infected femoral artery pseudoaneurysms. *J Vas Surg* 2001;33:990–3
15. Reddy DJ. Treatment of drug-related infected false aneurysms of the femoral artery--is routine revascularization justified? *J Vas Surg* 1988;8:344–5.

**Article Citation:** Hassan G, Ahmad I, Ahmad G. Ruptured infected femoral pseudoaneurysm in iv drug abusers: Ligation under local anesthesia. *JSZMC* 2018;9(1):1315-1317